SQUAMOUS CELL CARCINOMA OF PENIS LEADING TO AUTO AMPUTATION: A RARE PRESENTATION

Vibhor Goyal[1], Dinesh Mathur [2], Manisha Nijhawan [3], Puneet Agarwal[4], Shilpa Soni[5], Shifa Yadav[6], Akansha Singh[7]

HOW TO CITE THIS ARTICLE:
Vibhor Goyal, Dinesh Mathur, Manisha Nijhawan, Puneet Agarwal, Shilpa Soni, Shifa Yadav, Akansha Singh. "Squamous cell carcinoma of penis leading to auto amputation: a rare presentation". Journal of Evolution of Medical and Dental Sciences 2013; Vol. 2, Issue 51, December 23; Page: 10056-10059.

ABSTRACT: **INTRODUCTION:** Penile cancer is an uncommon malignancy in which malignant cells develop on the skin of penis. When penile cancer is left untreated, at an advanced stage it can have tragic consequences for the patient. **CASE PRESENTATION:** Our case report is an interesting presentation with clinical significance that emphasizes the need to diagnose and treat penile cancer in early stages. It is an unusual case of a neglected penile cancer in 63 year old man that led to auto amputation of penis. **CONCLUSION:** Emphasis must be placed on early diagnosis and treatment of the penile cancer.
KEYWORDS – Penile cancer, metastasis, squamous cell carcinoma, auto amputation.

INTRODUCTION – Squamous cell carcinoma is a cancer of a kind of epithelial cell, the squamous cell. Penile cancer is a relatively rare and uncommon malignancy[1]. It usually originates in the epithelium of the inner prepuce and glans[2]. In early stages, it is a slow growing cancer, and because it seldom interferes with voiding or erectile function, patient often presents late and conservative surgery is impossible[3]. The incidence of penile cancer increases abruptly in men aged 60 years or older and peaks in those aged 80 years[3]. Penile cancer is rare in western countries and accounts for 0.4% - 0.6% of all malignancies in the United States and Europe. In urban India the age adjusted incidence of penile cancer ranges from 0.7 – 2.3 cases per 100,000 men while in rural India it is 3 cases per 100,000 men, accounting for more than 6% of all the malignancies in this population[3]. Risk factors include AIDS[4], HPV[5], poor hygiene, chronic balanitis[6] , lichen sclerosis, long standing phimosis, underlying health conditions such as reactive arthritis, infections or diabetes, smoking and tobacco. Symptoms of penile cancer are variable with early lesions presenting as redness or change in colour of penis[7] , while foul smelling discharge or growth on penis that does not heal within four weeks(may look like a wart, ulcer or blister)[7] or bleeding from penis are late symptoms. Late lesions may metastasize to inguinal and pelvic lymph nodes[8].
The differential diagnosis includes basal cell carcinoma, Kaposi sarcoma, malignant melanoma, urethral carcinoma, psoriasis vulgaris, lichen planus, allergic contact dermatitis, lichen simplex chronicus and lichen nitidus.

CASE PRESENTATION – A 63 year old male patient, with long history of smoking, presented with a neglected penile lesion that led to auto amputation of penis with disturbed urinary function[Fig 1]. Patient was apparently well 2 to 3 years back when he noticed a small lesion over prepuce which gradually increased in size. Patient had difficulty in micturition with dysuria. Past history revealed left sided hemiparesis 14 years back from which he had recovered. Examination of genitalia revealed an exophytic indefinable mass with absence of penis. Chest X- ray was normal. HIV and HbsAg were

negative. Blood and serum profile were in normal range. Scrotum was normal with insignificant inguinal lymphadenopathy. Biopsy was suggestive of moderately differentiated squamous cell carcinoma. Patient underwent perianal urethrostomy in Mahatma Gandhi Medical College and Hospital in August 2013.



Fig. 1

DISCUSSION – Like many other malignancies, penile cancer can spread to other parts of the body. It is usually a primary malignancy, the initial place from where a cancer spreads to the body. Much less often it is a secondary malignancy, one in which the cancer has spread to penis from elsewhere. Penile cancer usually begins as a small lesion on the glans or prepuce. Lesions range from white to grey, irregular exophytic to reddish flat and ulcerated endophytic masses[3]. They gradually grow laterally along the surface and can cover the entire glans and prepuce before invading the corpora and shaft of the penis.

In addition to the dermatologic lesions, carcinoma of penis must be differentiated from several infectious lesions. Syphilitic chancre may present as a painless ulceration. Chancroid typically appears as a painful ulceration of the penis. Condylomata acuminate appears as exophytic, soft 'grape cluster' lesion anywhere on the penile shaft or glans. Biopsy can distinguish these lesions from carcinoma.

The TNM staging of penile cancer is as follows[9]:

TX: The primary tumor cannot be assessed.

T0: No evidence of primary tumor.

Tis: Carcinoma in situ.

Ta: Non invasive verrucous carcinoma, not associated with destructive invasion.

T1: Tumour invades subepithelial connective tissue.

T1a: Tumour invades subepithelial connective tissue without lymphovascular invasion and is not poorly differentiated or undifferentiated.

T1b: Tumour invades subepithelial connective tissue with/without lymphovascular invasion and is poorly differentiated or undifferentiated.

T2: Tumour invades corpus spongiosum/corpora cavernosa.

T3: Tumour invades urethra.

T4: Tumour invades other adjacent structures.

NX: Regional lymph nodes cannot be assessed.

N0: No palpable or visibly enlarged inguinal lymph node.

N1: Palpable mobile unilateral inguinal lymph node.

N2: Palpable mobile multiple or bilateral inguinal lymph node.

N3: Fixed inguinal nodal mass or pelvic lymphadenopathy, unilateral or bilateral.
M0: There is no distant metastasis.
M1: There is distant metastasis.

The staging of penile cancer is determined by the extent of tumour invasion, nodal metastasis and distant metastasis. The AJCC staging guidelines are as follows:
Stage 1: The cancer is moderately or well differentiated and only affects the subepithelial connective tissue.
Stage 2: The cancer is poorly differentiated, affects lymphatics or invades the corpora or urethra.
Stage 3a: There is deep invasion into the penis and metastasis in one lymph node.
Stage 3b: There is deep invasion into the penis and metastasis into multiple inguinal lymph nodes.
Stage 4: The cancer has invaded into structures adjacent to the penis, metastasized to pelvic nodes, or distant metastasis is present.

Microscopically tumours vary from well differentiated keratinizing tumour to solid anaplastic carcinoma with scanty keratinization[3]. Most tumours are highly keratinized and are of moderate differentiation. Poorly differentiated carcinomas have variable amount of spindle cells, giant cells, clear cells, small cells or glandular component[3].

In the reported case, H&E staining was done and biopsy features were consistent with high nuclear to cytoplasmic ratio, mitosis, high keratinization along with variable amount of spindle cells and giant cells(Fig 2 & 3)

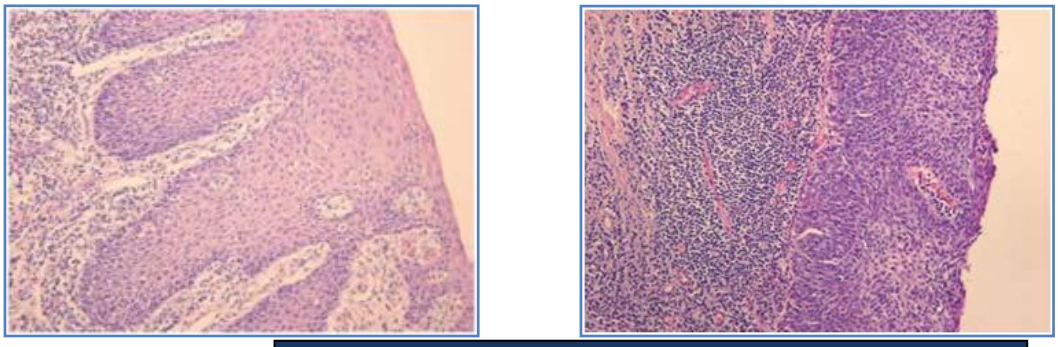

Fig. 2 and 3: Histopathological examination showed well differentiated squamous cells with keratinization.

Management involves surgical excision of the primary penile lesion, management of stage T4, high grade stage T3 or advanced stage T2 require radical surgery in the form of partial or total penectomy. Radiotherapy is most appropriate for small T1 or T2 lesions in patients unfit or unwilling to undergo surgery. Prognosis can range considerably for patients depending upon the stage of cancer.

CONCLUSION- We have presented a rare case presentation of Squamous Cell Carcinoma of penis leading to auto-amputation. Penile cancer can have devastating and psychological consequences for those affected. General awareness should be spread for early detection of these lesions.

REFERENCES –

1. 1.Zubeyde Rana Kaya , Sait Sager , Meltin Halac and Kerim Sonmezoglu "Disseminated metastatic penile squamous cell carcinoma detected by flurodeoxyglucose PET/computerized tomography" Indian journal Nucl Med 2012 july-sep;27(3):189-191.
2. Pizzocaro G, Algaba F, Horenblas S et al "EAU penile cancer guidelines" 2009.Eur Urol.2010;57:1002-12.[pubmed]
3. Stanley A Brosman , Bradely Fields Schwartz "Penile cancer" Medscape Reference, Sep 27,2012/446554-overview.
4. The American Cancer Society: Penile cancer "what are the risk factors for penile cancer"?(www.cancer.org/cancer/penile cancer/detailed guide/penile cancer-risk factors).
5. Pow sang MR, Ferreira U, Nardi AC "Epidemiology and natural history of penile cancer" J.Urology(august 2010) Urology 76(2 suppl 1).
6. Minhas S, Manseck A, Watya S "Penile cancer –prevention and premalignant conditions"(August 2010) Urology 76(2 suppl 1).
7. Pubmed Health (http://www.ncbi.nlm.nih.gov/pubmedhealth/PMH0001865/)Pub Med, Last reviewed : September 16,2011).
8. Daseler EH , Anson BJ, Remann AF"Radical excision of the inguinal and iliac lymph glands-a study based upon 450 anatomical dissections and upon supportive clinical observations" 1948;87:679-94.[pubmed]
9. G.Pizzocaro , F .Algaba , E.Solsona , S. Tana , H. Van Der Poel , N. Watkin , S. Horenblas "Guidelines On Penile Cancer" European Association Of Urology 2010.

AUTHORS:

1. Vibhor Goyal
2. Dinesh Mathur
3. Manisha Nijhawan
4. Puneet Agarwal
5. Shilpa Soni
6. Shifa Yadav
7. Akansha Singh

PARTICULARS OF CONTRIBUTORS:

1. Resident Doctor, Department of Skin & VD, Mahatma Gandhi Medical College & Hospital, Jaipur.
2. Professor and Head, Department of Skin & VD, Mahatma Gandhi Medical College & Hospital, Jaipur.
3. Associate Professor, Department of Skin & VD, Mahatma Gandhi Medical College & Hospital, Jaipur.
4. Resident Doctor, Department of Skin & VD, Mahatma Gandhi Medical College & Hospital, Jaipur.
5. Resident Doctor, Department of Skin & VD, Mahatma Gandhi Medical College & Hospital, Jaipur.
6. Resident Doctor, Department of Skin & VD, Mahatma Gandhi Medical College & Hospital, Jaipur.
7. Resident Doctor, Department of Skin & VD, Mahatma Gandhi Medical College & Hospital, Jaipur.

NAME ADDRESS EMAIL ID OF THE CORRESPONDING AUTHOR:

Dr Vibhor Goyal
Room no 208, type 4 A , PG Hostel,
Mahatma Gandhi Hospital, Sitapura, Jaipur
Email – drvibhorgoyal@gmail.com

Date of Submission: 31/10/2013.
Date of Peer Review: 02/11/2013.
Date of Acceptance: 10/12/2013.
Date of Publishing: 21/12/2013.